2014 SPR Postgraduate Course

Child Abuse & Not Child Abuse: Focus on Radiography

Moderators: Jeannette M. Perez-Rossello, MD
Peter J. Strouse, MD, FACR

A 7 month old infant presents with fussiness and a heart murmur. A radiograph of the chest was obtained which shows which of the following?

A. No abnormality

B. An acute rib fracture

C. A healing rib fracture

D. A rib fracture on indeterminate age

E. A clavicle fracture

RSNA®
Radiological Society of North America
POLL INFORMATION SLIDE

Answer: C. **A healing rib fracture**

Rational: There is a fracture of the lateral aspect of the left 7th rib. There is evidence of surrounding mature (hard) callus indicating healing (C).

Option A is incorrect because of the fracture

Option B is incorrect because of the callus.

Option D is incorrect because the hard callus would be inconsistent with a recent acute injury.

Option E is incorrect because the clavicles are normal.

References:

1. Barsness KA, Cha ES, Bensard DD, Calkins CM, Partrick DA, Karrer FM, et al. The positive predictive value of rib fractures as an indicator of nonaccidental trauma in children. J Trauma. 2003;54(6):1107-10.

2. Cadzow SP, Armstrong KL. Rib fractures in infants: red alert! The clinical features, investigations and child protection outcomes. Journal of Paediatrics & Child Health. 2000;36(4):322-6.

3. Williams RL, Connolly PT. In children undergoing chest radiography what is the specificity of rib fractures for non-accidental injury? Arch Dis Child. 2004;89(5):490-2.

4. Cosway B, Mathura N, Bredow M, Fraser J, Mott A, Rawlinson A, et al. Diagnostic indicators for NAI in children with RIB fractures; a retrospective analysis of 52 infants. Archives of Disease in Childhood. 2011;96(Suppl 1):A99.

5. Kemp AM, Dunstan F, Harrison S, Morris S, Mann M, Rolfe K, et al. Patterns of skeletal fractures in child abuse: systematic review. BMJ. 2008;337:a1518.

6. Strouse PJ, Boal DKB. Child Abuse. In: Coley BD, editor. Caffey's Pediatric Diagnostic Imaging. 12th ed. Philadelphia: Saunders; 2013. p. 1587-98.

A solitary rib fracture incidentally encountered in an otherwise normal child should *immediately* prompt which of the following?

A. Skeletal survey

B. Verbal conversation with the referring health care provider

C. Discussion with the family

D. Dictation and finalization

E. Chest CT

RSNA®
Radiological Society of North America
POLL INFORMATION SLIDE

Correct answer is B. Verbal conversation with the referring health care provider

Rational: Rib fractures are strongly associated with child abuse in infancy. The findings should be immediately communicated to the ordering health care provider (B).

Option A is incorrect since the skeletal survey should be done only after the clinician is informed of the finding and a skeletal survey has been requested. If abuse is a concern, a skeletal survey is usually the next imaging study

Option C is incorrect because the findings are best discussed with the family in the clinical context by the referring clinician/member of the child protection team.

Option D is incorrect since the discussion with the clinician may inform the final dictation and the conversation should be documented in the report.

Option E is incorrect since chest CT is generally reserved for a small minority of patients as a problem solving tool.

This infant also had multiple classic metaphyseal lesions and forearm fractures on the subsequent skeletal survey and a mandated report was filed.

References:

1. American Academy of Pediatrics Section on Radiology (2009). "Diagnostic imaging of child abuse." Pediatrics 123(5): 1430-1435.

2. American College of Radiology (2011). ACR–SPR Practice Guideline for Skeletal Surveys in Children Revised 2011 (Resolution 54)*. Reston, VA, American College of Radiology: 1-6

3. American College of Radiology Expert Panel on Pediatric Imaging (2011). ACR Appropriateness Criteria on suspected physical abuse-child. J Am Coll Radiol, American College of Radiology. 8: 87-94.

4. Wootton-Gorges SL, Stein-Wexler R, Walton JW, Rosas AJ, Coulter KP, Rogers KK. Comparison of computed tomography and chest radiography in the detection of rib fractures in abused infants. Child Abuse Negl. 2008;32(6):659-63.

5. American College of Radiology. ACR Practice Guideline for Communicating of Diagnostic Imaging Findings (Res. 11). American College of Radiology: ACR Standards. Reston, VA: American College of Radiology; 2010.

Which of the following is true regarding the findings?

A. Fracture possibly associated with child abuse
B. Classic metaphyseal lesion and definitely child abuse
C. Probable metabolic abnormality such as rickets
D. Normal finding with metaphyseal step-off
E. Osteomyelitis

RSNA®
Radiological Society of North America
POLL INFORMATION SLIDE

Answer is D. **Normal finding with metaphyseal step-off**

The radiograph depicts a **normal metaphyseal step-off** where there is a focal paucity of cortical bone due to subperiosteal bone collar.

Option A is <u>not</u> correct. This finding does not represent a fracture and therefore child abuse is not suggested.

Option B is <u>not</u> correct. This finding does not represent a classic metaphyseal lesion and therefore child abuse is not suggested.

Option C is <u>not</u> correct. There are no findings to suggest a metabolic abnormality such as metaphyseal cupping and flaring to suggest rickets.

Option D is correct. This finding is a normal metaphyseal step-off with 90 degree angulation at the metaphysic and commonly occurs in the distal femur.

Option E is <u>not</u> correct. There is no lucency or periosteal reaction to suggest osteomyelitis.

References:

1. Kleinman PK, Belanger PL, Karellas A, Spevak MR. AJR Am J Roentgenol. 1991 Apr;156(4):781-3. Normal metaphyseal radiologic variants not to be confused with findings of infant abuse.

2. Kleinman PK, Sarwar ZU, Newton AW, Perez-Rossello JM, Rebello G, Herliczek TW. Metaphyseal fragmentation with physiologic bowing: a finding not to be confused with the classic metaphyseal lesion. AJR Am J Roentgenol. 2009 May;192(5):1266-8

3. Dwek JR. The radiographic approach to child abuse.Clin Orthop Relat Res. 2011 Mar;469(3):776-89.

Considering the appearance of the radial aspect of the distal ulnar shaft, the best diagnosis is which of the following

A. Rickets with co-existent scurvy
B. Rickets with associated primary hyperparathyroidism
C. Rickets with associated secondary hyperparathyroidism
D. Metaphyseal chondrodysplasia type Schmid
E. Healing fracture in an abused child

RSNA®
Radiological Society of North America
POLL INFORMATION SLIDE

Answer: C. Rickets with associated secondary hyperparathyriodism

Explanation:

In addition to florid rickets, the finding along the distal ulna is subperiosteal bone resorption, which is indicative of hyperparathyroidism. In rickets, decreased Ca absorption from vitamin D insufficiency initially leads to hypcalcemia. The hyperparathyroidism which then develops is hence compensatory (secondary hyperparathroidism). There are no findings of scurvy which characteristically has a very well defined zone of provisional calcification. In metaphyseal chondrodysplasia type Schmid, calcium and phosphorus are normal, and hence there is no stimulus for secondary hyperparathyroidism to develop. This does not have the appearance of a healing fracture.

Reference:

Shore RM, Chesney RW. Rickets: Part II. Pediatr Radiol 2013; 43:152-172

What is the best answer if these images reflect the only radio-graphic abnormalities for an infant patient?

A. Patients A and B have no radiographic evidence of physical abuse, the findings are normal variants.
B. Patients A and B have skeletal findings concerning for physical abuse
C. Patient B has skeletal findings concerning for physical abuse
D. Patient B has skeletal findings concerning for rickets
E. Patient B has skeletal findings concerning for osteogenesis imperfecta

Patient A

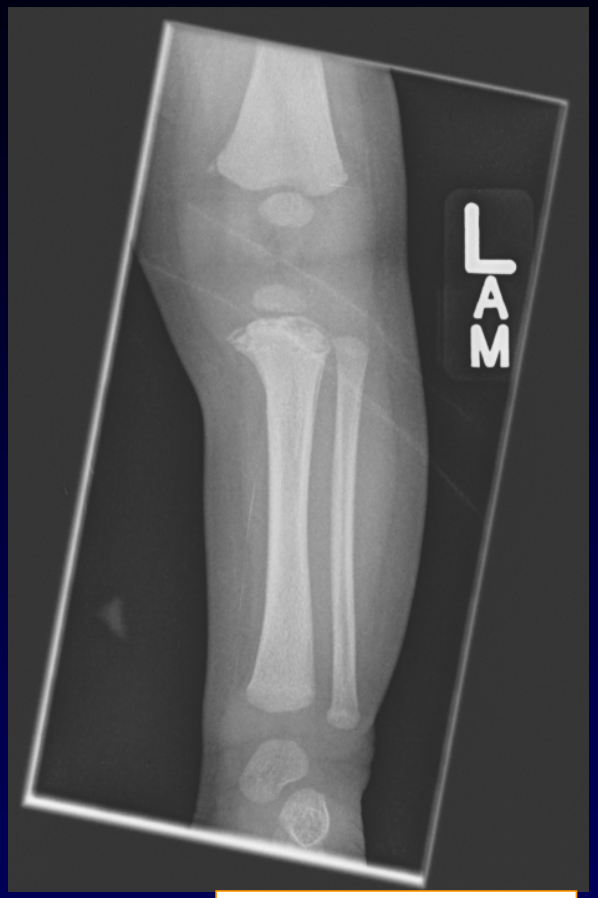

P

RSNA®
Radiological Society of North America
POLL INFORMATION SLIDE

Answer is C. **Patient B has skeletal findings concerning for physical abuse**

The x-ray for Patient A demonstrates normal bone mineralization with ulnar cupping, which is a normal variant. The x-ray for Patient B demonstrates normal bone mineralization with classic metaphyseal fractures of the left distal femur and the left proximal tibia.

Option A is not correct. Only the findings in Patient A's x-rays demonstrate a normal variant. Metaphyseal fractures are not variants of normal, and instead are fractures that result of shearing stress on the metaphysis.

Option B is not correct. Classic metaphyseal fractures have a high specificity for physical abuse. These findings are only present in patient B's x-ray.

Option C is correct. Patient B has classic metaphyseal fractures of the distal left femur and proximal right tibia. These fractures result from shearing stress on the knee in this patient. Such stress in a nonambulatory child is suspicious for nonaccidental trauma.

Option D is not correct. There is no radiographic evidence of rickets in patient B. The bones are well mineralized radiographically, and there is no fraying of the metaphyses

Option E is not correct. Osteogenesis imperfect is a disorder of type I collagen resulting in fragile bones, osteopenia and fractures. Metaphyseal fractures are more specific for child abuse than OI. Children with type 2 OI usually do not survive the perinatal period. Those with Type 3 OI had profound skeletal fragility with growth retardation and bone deformation. Those with types 1 and 4 have variable degrees of skeletal fragility and may or may not have blue sclera.

REFERENCES:

1. Bishop, N, sprig, A. Dalton, A. Unexplained fractures in infancy: looking for fragile bones. *Arch Dis Child* 2007; 92: 251-256.

2. Greeley, CS, Donaruma-Kwoh, M., Vettimattam, M, et. Al. Fractures at diagnosis in infants and children with osteogenesis imperfect. *J Pediatr Orthop* 2013; 33(1): 32-36.

3. Kleinman, PK, Perez-Rossello, JM, Newton, AW et al. Prevalence of the classic metaphyseal lesion in infants at low versus high risk for abuse. *Am J Roentgenol* 2011; 197(4): 1005-1008.

4. Slovis, TL, Chapman, S. Evaluating the data concerning vitamin D insufficiency/deficiency and child abuse. *Pediatr Radiol* 2008; 38: 1221-1224.

Which of the following statements regarding follow-up skeletal surveys in infants suspected of child abuse is FALSE?

A. The follow-up skeletal survey usually identifies additional high specificity fractures, namely rib fractures and CMLs.

B. If the initial skeletal survey is normal, there is no need for a follow-up study.

C. The follow-up skeletal survey can clarify if a finding is a fracture or a normal variant.

D. The ACR recommends a 2-week follow-up skeletal survey in children less than 2 years of age suspected of child abuse.

RSNA®
Radiological Society of North America
POLL INFORMATION SLIDE

Correct Answer: B

A. **The follow-up skeletal survey usually identifies additional high specificity fractures, namely rib fractures and CMLs.** ***(True, the follow-up skeletal survey adds new information in up to 60% of cases, and 62-91% of the new information are rib fractures or classic metaphyseal lesions)***

B. **If the initial skeletal survey is normal, there is no need for a follow-up study.** ***(False, 12% of follow up studies done after a normal skeletal survey can show additional information)***

C. **The follow-up skeletal survey can clarify if a finding is a fracture or a normal variant.** ***(True, a fracture will change and show evidence of healing whereas a variant will remain unchanged)***

D. **The ACR recommends a 2-week follow-up skeletal survey in children less than 2 years of age suspected of child abuse.** ***(True, see ACR standards)***

References

1. Kleinman PK et al. Follow-up skeletal surveys in suspected child abuse. AJR Am J Roentgenol 1996; 167:894-896.

2. Zimmerman S et al. Utility of follow-up skeletal surveys in suspected child physical abuse evaluations. Child Abuse Negl 2005;29:1075-1083.

3. American College of Radiology. ACR Appropriateness Criteria Suspected Physical Abuse 2012; http://www.acr.org/~/media/ACR/Documents/AppCriteria/Diagnostic/SuspectedPhysicalAbuseChild.pdf

4. Bennett BL et al. Retrospective review to determine the utility of follow-up skeletal surveys in child abuse evaluations when the initial skeletal survey is normal. BMC Res Notes 2011;4:354.

5. Singh R et al. Assessing the use of follow-up skeletal surveys in children with suspceted physical abuse. J Trauma Acute Care Surg 2012;73:972-976.

The thick peripheral osseous component of the classic metaphyseal lesion (CML) is due to which of the following?

A. Radiologic zone of provisional calcification (ZPC)
B. Histologic ZPC
C. Subperiosteal bone collar (SPBC)
D. Physis
E. Epiphysis

RSNA®
Radiological Society of North America
POLL INFORMATION SLIDE

Answer:

C. Subperiosteal bone collar

As the CML fracture line passes peripherally toward the cortex, it veers away from the physis to undercut an osseous peripheral segment that encompasses the Subperiosteal bone collar (SPBC). Thus, the peripheral component of the CML is due to the SPBC.

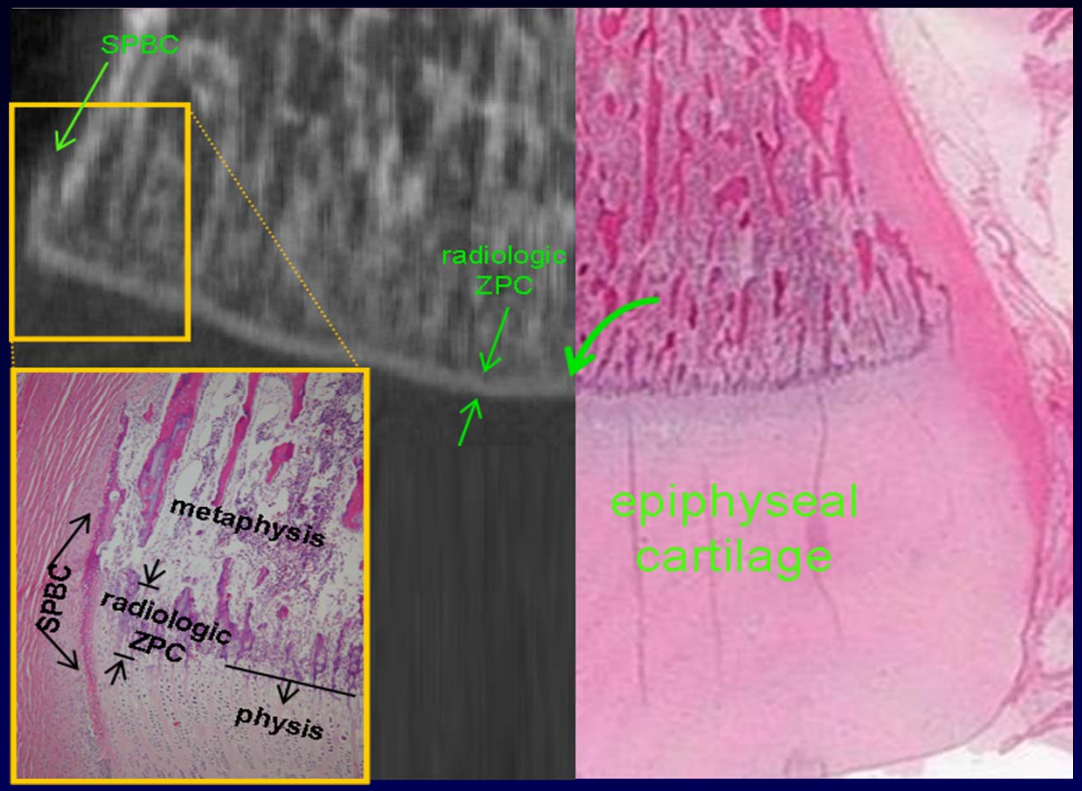

Reference:

Tsai A, McDonald A, Rosenberg A, Gupta R, Kleinman P. High-resolution CT with histopathologic correlates of the classic metaphyseal lesion of infant abuse. *Pediatr Radiol* 2014; 44(2): 124-140.

The thin inner radiodense component of the CML is mostly due to which of the following?

A. Radiologic Zone of Provisional Calcification (ZPC)

B. Histologic ZPC

C. Subperiostial Bone Collar (SPBC)

D. Physis

E. Epiphysis

RSNA®
Radiological Society
of North America
POLL INFORMATION SLIDE

Answer:

A. Radiologic Zone of Provisional Calcification (ZPC)

The CML consists of a fracture occurring in a planar fashion through the most immature portion of the metaphysis in the region of the trabecular transition zone, disrupting the delicate trabeculae composed of central calcified cartilage cores covered by thin layers of newly formed bone. The radiographically visible calcium density of the fragment centrally consists mostly of the radiologic ZPC.

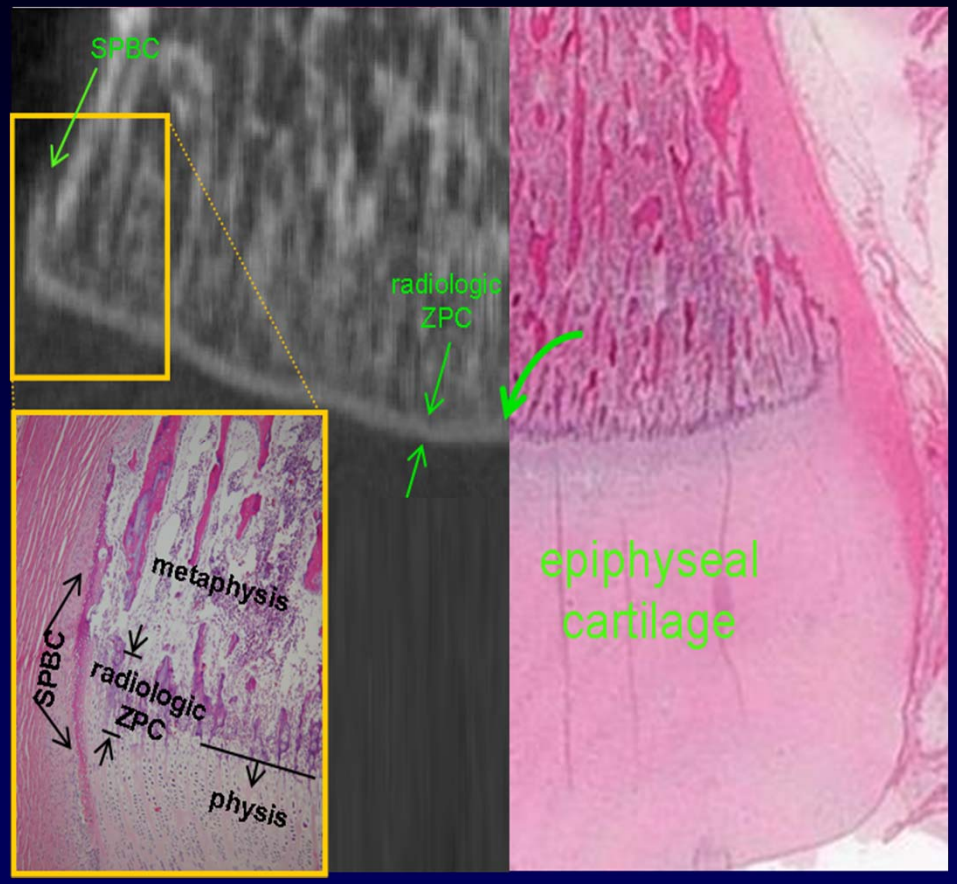

Reference:

Tsai A, McDonald A, Rosenberg A, Gupta R, Kleinman P. High-resolution CT with histopathologic correlates of the classic metaphyseal lesion of infant abuse. *Pediatr Radiol* 2014; 44(2): 124-140.

This AP radiograph of the left clavicle in a young infant demonstrates which of the following?

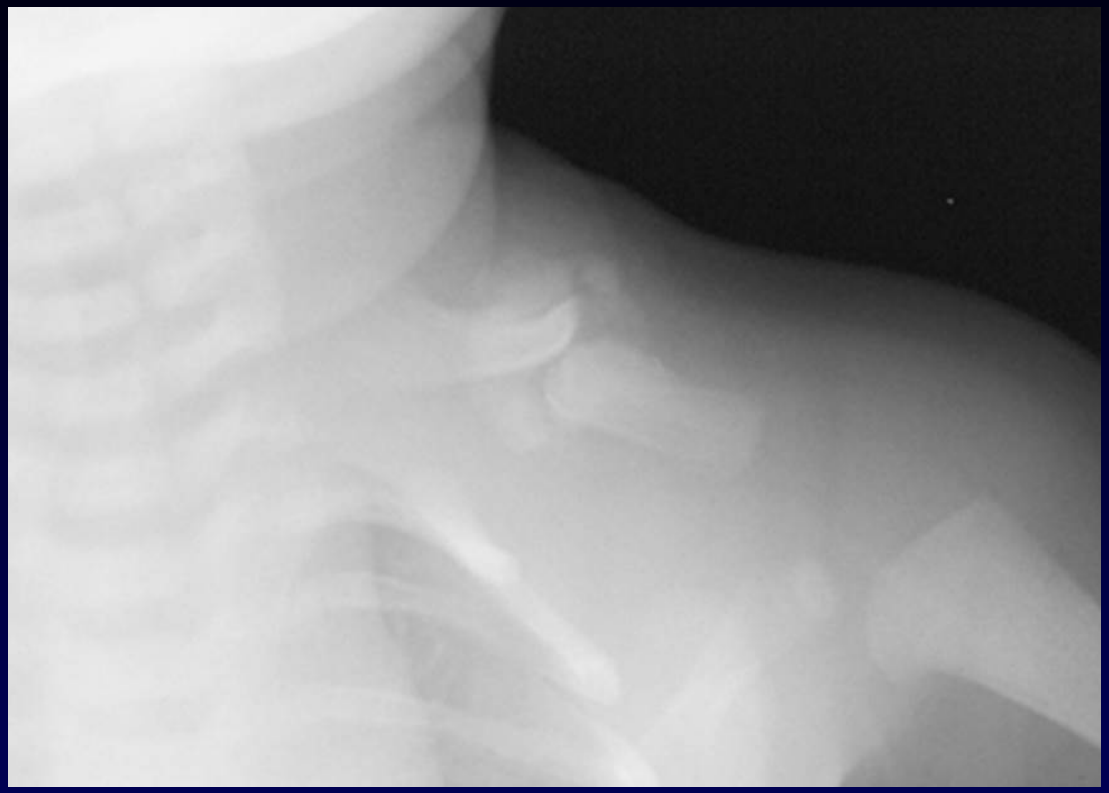

A. No evidence of healing.
B. Subperiosteal new bone formation.
C. Soft/intermediate callus formation.
D. Hard/mature callus formation.
E. Advanced remodeling.

RSNA®
Radiological Society of North America
POLL INFORMATION SLIDE

Answer is C. **Soft/intermediate callus formation.**

Option A is incorrect. Signs of healing are evident.

Option B is incorrect. Subperiosteal new bone formation (SPNBF) is linear in orientation, with either a single-layered or multilayered/lamellated configuration. The presence of SPNBF indicates that a fracture is in a relatively earlier stage of healing. In a young infant, SPNBF is typically first seen between 7 – 10 days following injury.

Option C is correct. The radiograph shows fluffy/cloud-like mineralization in a circular configuration around the fracture margins. This is consistent with soft/intermediate callus formation in this 13-day-old infant who sustained birth related trauma. In a young infant, soft callus typically first appears between 9 – 15 days following injury.

Option D is incorrect. Hard/mature callus has a dense trabecular matrix, similar to that of normal bone. The presence of hard callus indicates that a fracture is in a relatively more advanced stage of healing. In a young infant, hard callus typically first appears between 14 – 21 days following injury.

Option E is incorrect. With advanced remodeling, callus thickness has decreased, the medullary cavity has been reconstituted, and the cortex approximates the configuration of the cortex of the adjacent uninjured bone or a contralateral counterpart. In a young infant, advanced remodeling may be seen in as little as 2 months following injury.

References:

1. Walters MM, Forbes P, Buonomo C, Kleinman PK. Healing patterns of clavicular birth injuries as a guide to fracture dating in cases of possible infant abuse. Pediatric Radiology. In Press.

2. O'Connor JF, Cohen J. Dating fractures. In: Kleinman PK, editor. Diagnostic Imaging of Child Abuse. 2nd ed. St. Louis: Mosby; 1998. p. 168-77.

This AP radiograph of the left clavicle in a young infant demonstrates which of the following?

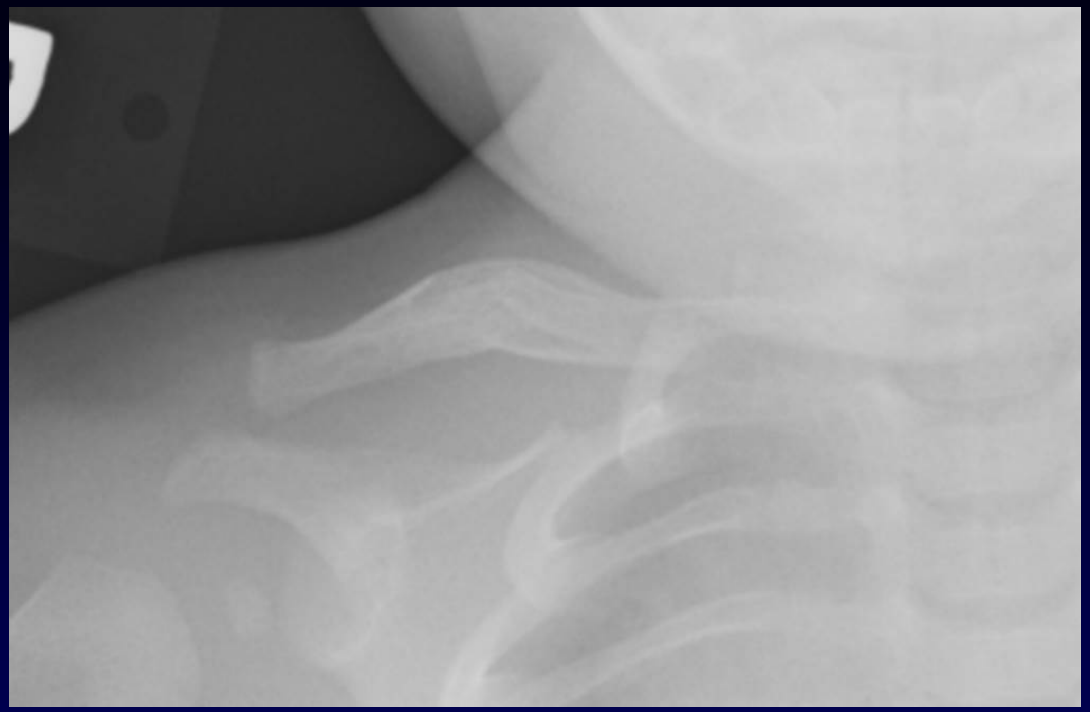

A. No evidence of healing.
B. Subperiosteal new bone formation.
C. Soft callus formation.
D. Intermediate callus formation.
E. Advanced remodeling.

RSNA®
Radiological Society of North America
POLL INFORMATION SLIDE

Answer is E. **Advanced remodeling.**

Option A is incorrect. Signs of healing are evident.

Option B is incorrect. Subperiosteal new bone formation (SPNBF) is linear in orientation, with either a single-layered or multilayered/lamellated configuration. The presence of SPNBF indicates that a fracture is in a relatively earlier stage of healing. In a young infant, SPNBF is typically first seen between 7 – 10 days following injury.

Options C and D are incorrect. Soft/intermediate callus appears as fluffy/cloud-like mineralization in a circular configuration around the fracture margins. With early callus formation, a trabecular matrix is not seen. In a young infant, soft/intermediate callus is typically first seen between 9 – 15 days following injury.

Option E is correct. With advanced remodeling, callus thickness has decreased, the medullary cavity has been reconstituted, and the cortex approximates the configuration of the cortex of the adjacent uninjured bone or a contralateral counterpart. In a young infant, advanced remodeling may be seen in as little as 2 months following injury. This 77-day-old infant sustained birth related trauma.

References:

1. Walters MM, Forbes P, Buonomo C, Kleinman PK. Healing patterns of clavicular birth injuries as a guide to fracture dating in cases of possible infant abuse. Pediatric Radiology. In Press.

2. O'Connor JF, Cohen J. Dating fractures. In: Kleinman PK, editor. Diagnostic Imaging of Child Abuse. 2nd ed. St. Louis: Mosby; 1998. p. 168-77.

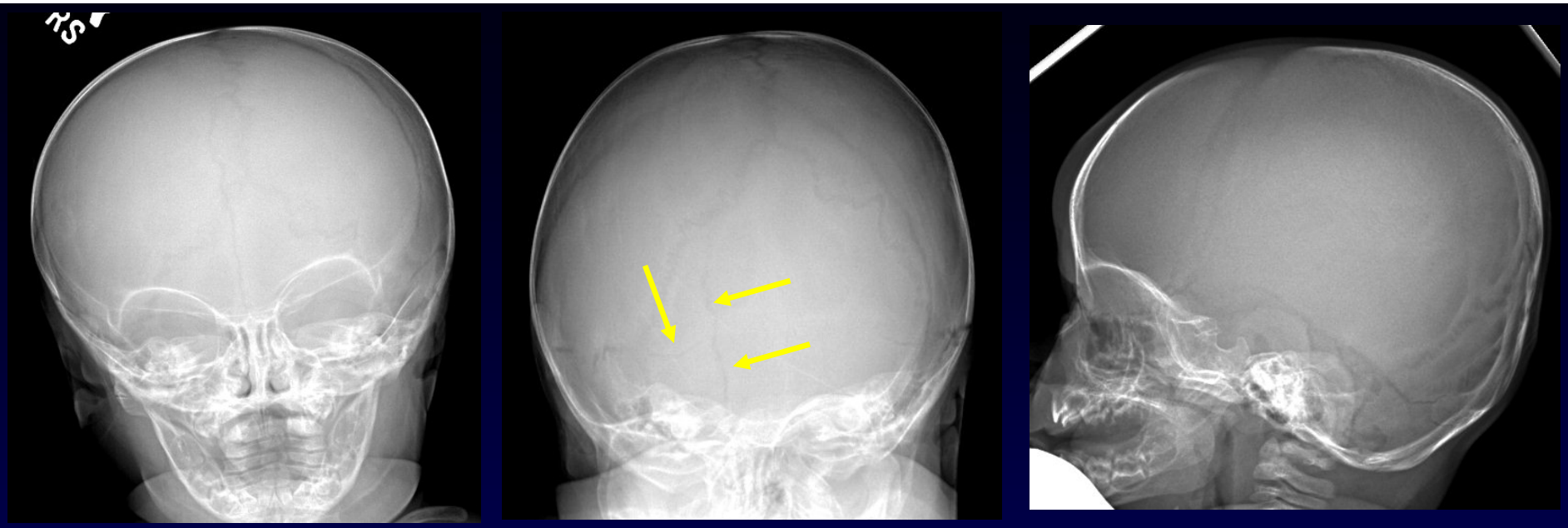

Due to concerns of physical abuse, a skeletal survey was performed on this 5-month-old boy in the Emergency Room.

The Emergency Room physician has preliminarily reviewed the images and marked a suspected complex fracture of the occipital bone.

What is marked by the arrows?

A. The mendosal suture
B. The metopic suture
C. The sagittal suture
D. A fracture of the frontal bone
E. A fracture of the occipital bone

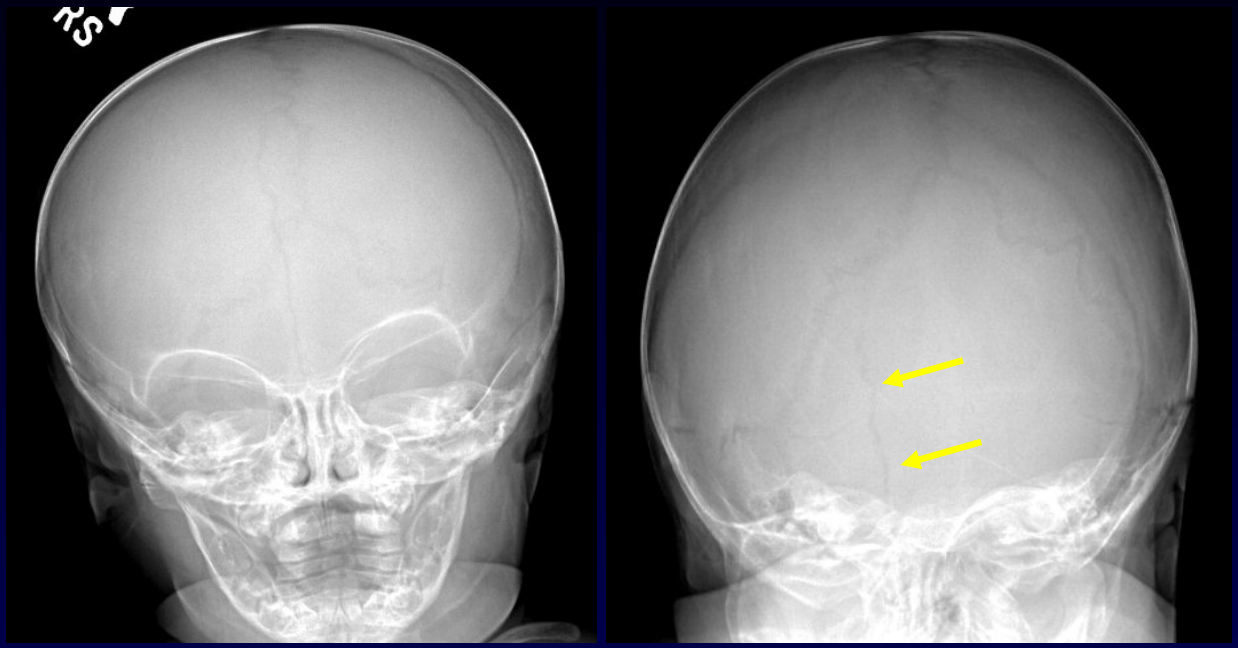

RSNA®
Radiological Society of North America
POLL INFORMATION SLIDE

Metopic Suture

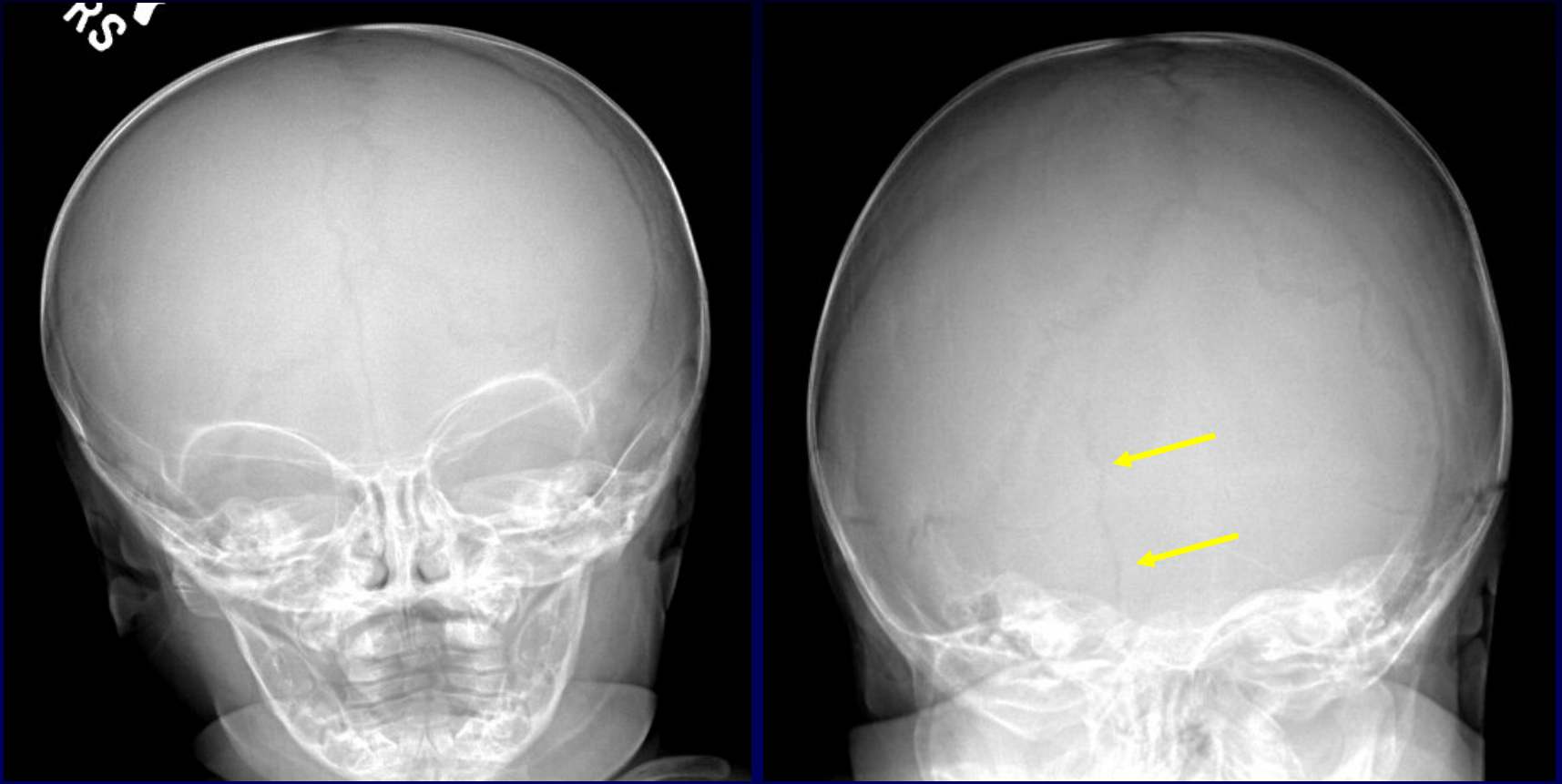

Answer is B. The metopic suture. The metopic suture divides the frontal bone. The suture fuses and is obscured by one year of age in most patients. The course of the line is not as straight as a fracture. There is adjacent sclerosis, which would not be seen with an acute fracture.

Option A is not correct: The mendosal sutures are located within the occipital bones and are remnants of transverse occipital suture between the interparietal and supraoccipital portions of the embryonic occipital bone. They normally fuse by 6-years of age. The mendosal sutures are transversely oriented and usually symmetric. In this case, a symmetric mendosal suture is also seen on the left. The mendosal sutures are also visualized on the lateral view at their expected location.

Option C is not correct: The sagittal suture is located between the parietal bones extending from the anterior fontanelle to the posterior fontanelle in an infant. In this case, the line extends beyond the expected location of the sagittal suture projecting within frontal and/or occipital bone.

Option D is not correct: The course of the line is not as straight as a fracture. There is adjacent sclerosis, which would not be seen with an acute fracture. While a healing fracture, might appear similar, the line corresponds to the expected location of the metopic suture, a normal structure.

Option E is not correct: The course of the line is not as straight as a fracture. There is adjacent sclerosis, which would not be seen with an acute fracture. While a healing fracture, might appear similar, the line corresponds to the expected location of the metopic suture, a normal structure. On the AP view, the line extends beyond the lambdoid suture and therefore beyond the occipital bone.

REFERENCES:

1. Choudhary AK, Jha B, Boal DK, Dias M. Occipital sutures an its variations: the value of 3D-DT and how to differentiate it from fractures using 3D-CT? Surg Radiol Anat 2010;32:807-816

2. Sanchez T, Stewart D, Walvick M, Swischuk L. Skull fracture vs. accessory sutures: how can we tell the difference? Emerg Radiol 2010;17:413-418

3. Nakahara K, Utsuki S, Shimizu S, et al. Age dependence of fusion of primary occipital sutures: a radiographic study. Childs Nerv Syst 2006;22:1457-1459

4. Allen WE 3rd, Kier EL, Rothman SL. Pitfalls in the evaluation of skull trauma. A review. Radiol Clin North Am 1973;11:479-503

What is marked by the arrow?

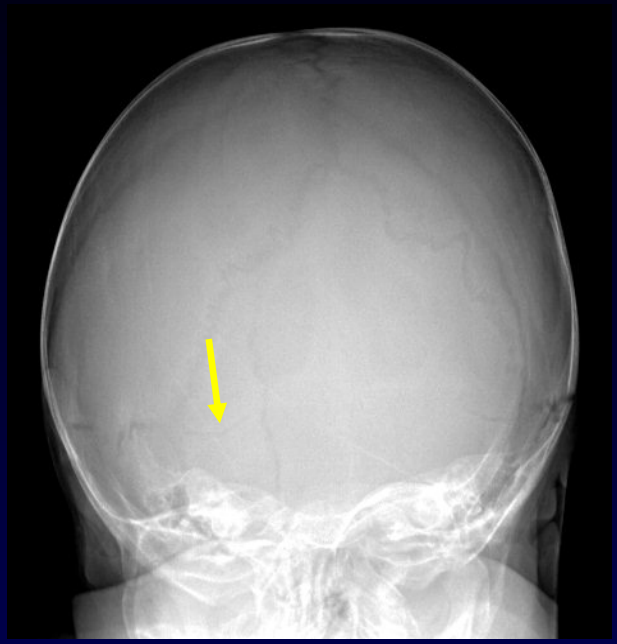

A. The mendosal suture
B. The metopic suture
C. The posterior intraoccipital synchondrosis
D. The anterior intraoccipital synchondrosis
E. A fracture of the occipital bone

RSNA®
Radiological Society of North America
POLL INFORMATION SLIDE

What is marked by the arrow?

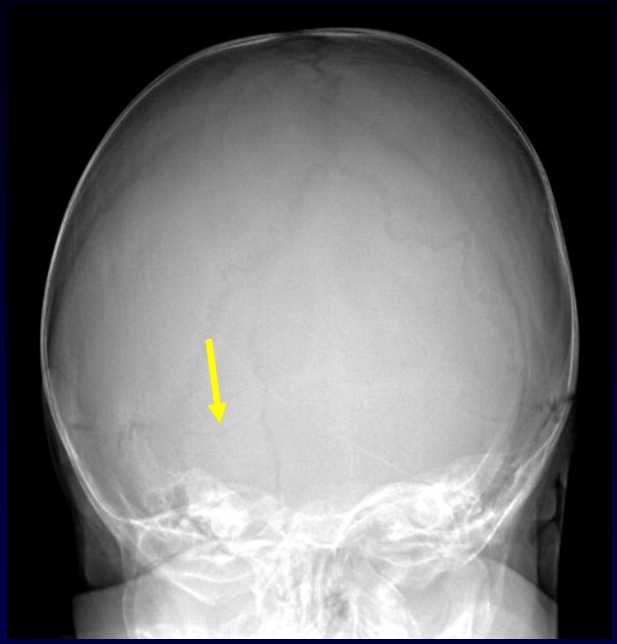

A. The mendosal suture
B. The metopic suture
C. The posterior intraoccipital synchondrosis
D. The anterior intraoccipital synchondrosis
E. A fracture of the occipital bone

RSNA®
Radiological Society of North America
POLL INFORMATION SLIDE

Mendosal Suture

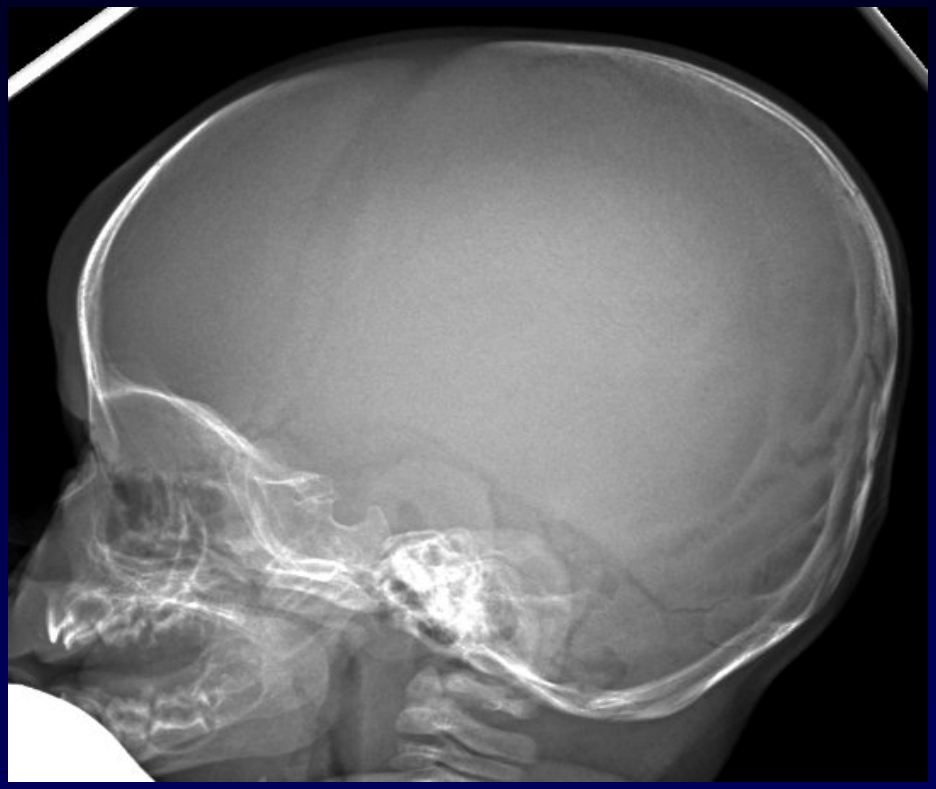

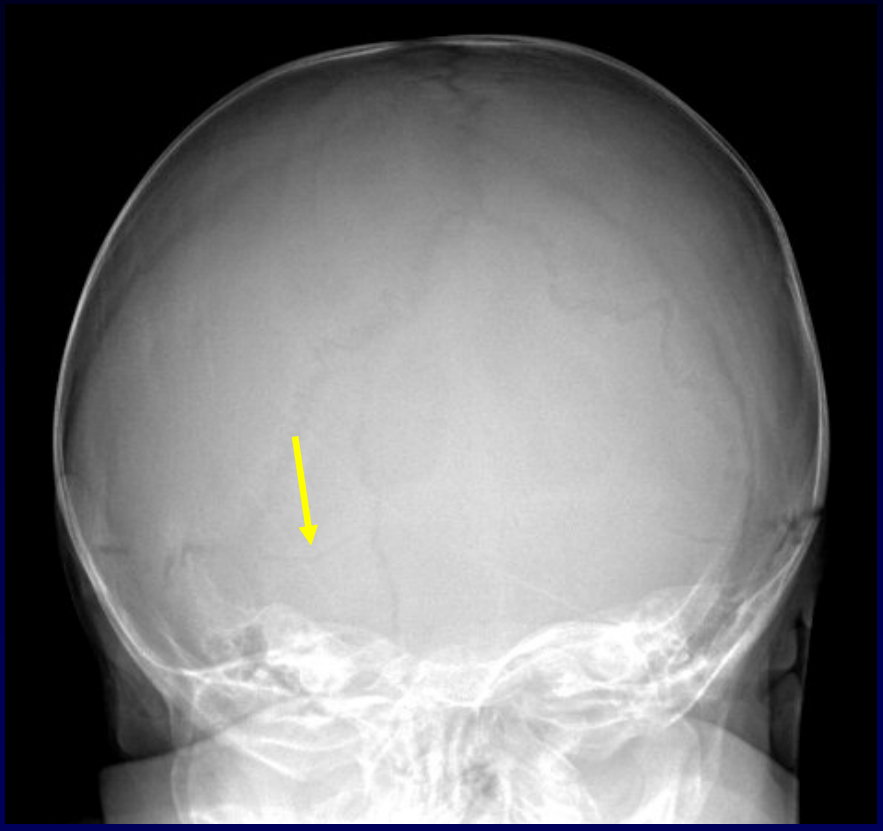

Answer is A. **The mendosal suture.** The mendosal sutures are located within the occipital bones and are remnants of transverse occipital suture between the interparietal and supraoccipital portions of the embryonic occipital bone. They normally fuse by 6-years of age. The mendosal sutures are transversely oriented and usually symmetric. In this case, a symmetric mendosal suture is also seen on the left. The mendosal sutures are also visualized on the lateral view at their expected location.

Option B is incorrect: The metopic suture divides the frontal bone and is sagittally oriented, not transverse. The suture fuses and is obscured by one year of age in most patients. The course of the line is not as straight as a fracture. There is adjacent sclerosis, which would not be seen with an acute fracture.

Option C is incorrect. This is not the correct location of the posterior intraoccipitial synchondrosis. It is located closer to the foramen magnum, but still posterior to it and is between the supraoccipital and exoccipital portions of the occipital bone.

Option D is incorrect. This is not the correct location of the anterior intraoccipitial synchondrosis. It is located between the exoccipital and basioccipital portions of the occipital bone at the anterior aspect of the foramen magnum.

Option E is incorrect. This structure is a normal anatomic structure, the mendosal suture, at a normal anatomic location. On the Townes view, it is symmetric, unlike a fracture.

REFERENCES:

1. Choudhary AK, Jha B, Boal DK, Dias M. Occipital sutures an its variations: the value of 3D-DT and how to differentiate it from fractures using 3D-CT? Surg Radiol Anat 2010;32:807-816

2. Sanchez T, Stewart D, Walvick M, Swischuk L. Skull fracture vs. accessory sutures: how can we tell the difference? Emerg Radiol 2010;17:413-418

3. Nakahara K, Utsuki S, Shimizu S, et al. Age dependence of fusion of primary occipital sutures: a radiographic study. Childs Nerv Syst 2006;22:1457-1459

4. Allen WE 3rd, Kier EL, Rothman SL. Pitfalls in the evaluation of skull trauma. A review. Radiol Clin North Am 1973;11:479-503

The most important physiological function of vitamin D is to enhance which of the following?

A. Endochondral ossification
B. Bone mineralization by upregulating osteoblast activity
C. Circulating calcium levels by decreasing renal calcium excretion
D. Circulating calcium levels by mobilizing mineral from bone
E. Intestinal absorption of calcium

RSNA®
Radiological Society of North America
POLL INFORMATION SLIDE

Answer E

A. Endochondral ossification

B. Bone mineralization by upregulating osteoblast activity

C. Circulating calcium levels by decreasing renal calcium excretion

D. Circulating calcium levels by mobilizing mineral from bone

E. Intestinal absorption of calcium

References: Shore RM, Chesney RW. Rickets: Part I. Pediatr Radiol 2013;43:140-151; Holick MF. Vitamin D deficiency. N Engl J Med. 2007;357:266-81

References:

Shore RM, Chesney RW. Rickets: Part I. Pediatr Radiol 2013;43:140-151

Holick MF. Vitamin D deficiency. N Engl J Med. 2007;357:266-81

The thin inner radiodense component of the CML is mostly due to which of the following?

A. Radiologic Zone of Provisional Calcification (ZPC)

B. Histologic ZPC

C. Subperiostial Bone Collar (SPBC)

D. Physis

E. Epiphysis

RSNA®
Radiological Society
of North America
POLL INFORMATION SLIDE

The radiodense material in the medial aspect of the proximal tibial physeal region is best explained by which of the following?

A. Newly formed metaphyseal bone in a patient with healing rickets
B. Mineralized but not ossified physeal cartilage in a patient with active rickets
C. Callus from a healing CML in an abused child
D. Bucket handle fragment of an acute CML in an abused child
E. Combined acute and healing fractures in an abused child

RSNA®
Radiological Society of North America
POLL INFORMATION SLIDE

Answer: B **Mineralized but not ossified physeal cartilage in a patient with active rickets**

Explanation:

This material does not have the appearance of trabecular bone. Rather it has a more amorphous appearance and is partially mineralized cartilage which has built up due to the ossification defect of rickets. There is no evidence of a fracture. This does not the appearance of callus for a healing fracture.

Reference : Shore RM, Chesney RW. Rickets: Part II. Pediatr Radiol 2013; 43:152-172

Reference:

Shore RM, Chesney RW. Rickets: Part II. Pediatr Radiol 2013; 43:152-172

A 17-month-old with right knee pain and refusal to bear weight on right lower extremity. Which of the following is most likely?

A. Severe rickets with fracture, most likely an insufficiency fracture
B. Osteogenesis imperfecta with fracture, most likely an insufficiency fracture
C. Scurvy with fracture, most likely insufficiency an fracture
D. Femur fracture in young infant, suspicious for abuse
E. Femoral fracture suspicious for abuse despite coexistent metabolic bone disease.

RSNA®
Radiological Society of North America
POLL INFORMATION SLIDE

Answer: A

A. Severe rickets with fracture, most likely an insufficiency fracture

B. Osteogenesis imperfecta with fracture, most likely an insufficiency fracture

C. Scurvy with fracture, most likely insufficiency an fracture

D. Femur fracture in young infant, suspicious for abuse

E. Femoral fracture suspicious for abuse despite coexistent metabolic bone disease.

References:

Shore RM, Chesney RW. Rickets: Part I. Pediatr Radiol 2013;43:140-151

Shore RM, Chesney RW. Rickets: Part II. Pediatr Radiol 2013; 43:152-172

Which of the following statements regarding follow-up skeletal surveys for suspected abuse is FALSE?

A. The skull radiographs are not included in the follow-up skeletal survey

B. Fractures can be missed if the SPR-ACR guidelines are not followed or if the images are not of high quality.

C. The follow-up skeletal survey adds additional information in 15-60% of cases.

D. The initial and follow-up skeletal survey may be limited by not including images of the hands, feet, pelvis and spine.

RSNA®
Radiological Society of North America
POLL INFORMATION SLIDE

Correct Answer: D

A. **The skull radiographs are not included in the follow-up skeletal survey.** ***(True, see ACR standards)***

B. **Fractures can be missed if the SPR-ACR guidelines are not followed or if the images are not of high quality.** ***(True, see ACR standards)***

C. **The follow-up skeletal survey adds additional information in 15-60% of cases.** ***(True, see Harper, Harlan and Kleinman references)***

D. **The initial and follow-up skeletal survey may be limited by not including images of the hands, feet, pelvis and spine.** ***(False, Differing studies on this topic, Karmazyn proposed this; Kleinman, Harlan and Lindberg papers differ. So far there is no change in the ACR-SPR guidelines to limit the images in the follow-up study)***

References

1. American College of Radiology. ACR-SPR Practice Guidelines for Skeletal Surveys in Children. 2011; http://www.acr.org/~/media/ACR/Documents/PGTS/guidelines/Skeletal_Surveys.pdf.

2. Harper NS et al. The utility of follow-up skeletal surveys in child abuse. Pediatrics 2013;131:e672-678

3. Harlan SR, Nixon GW, Campbell KA, et al. Follow-up skeletal surveys for nonaccidental trauma: can a more limited survey be performed? Pediatr. Radiol. 2009;39(9):962-968.

4. Karmazyn B, Lewis ME, Jennings SG, Hibbard RA, Hicks RA. The prevalence of uncommon fractures on skeletal surveys performed to evaluate for suspected abuse in 930 children: should practice guidelines change? AJR Am J Roentgenol 2011; 197:W159-163.

5. Kleinman PK, Morris NB, Makris J, Moles RL, Kleinman PL. Yield of radiographic skeletal surveys for detection of hand, foot, and spine fractures in suspected child abuse. AJR Am J Roentgenol 2013;200(3):641-4.

What findings for this 3-month old term infant would you include in your report?

A. Left upper lobe consolidation
B. Osteopenia with pathologic rib fractures and metaphyseal cupping and fraying
C. Multiple posterior and lateral rib fractures
D. Multiple posterior and lateral rib fractures in different stages of healing
E. Multiple posterior and lateral rib fractures in different stages of healing and a metaphyseal corner fracture of the left proximal humerus

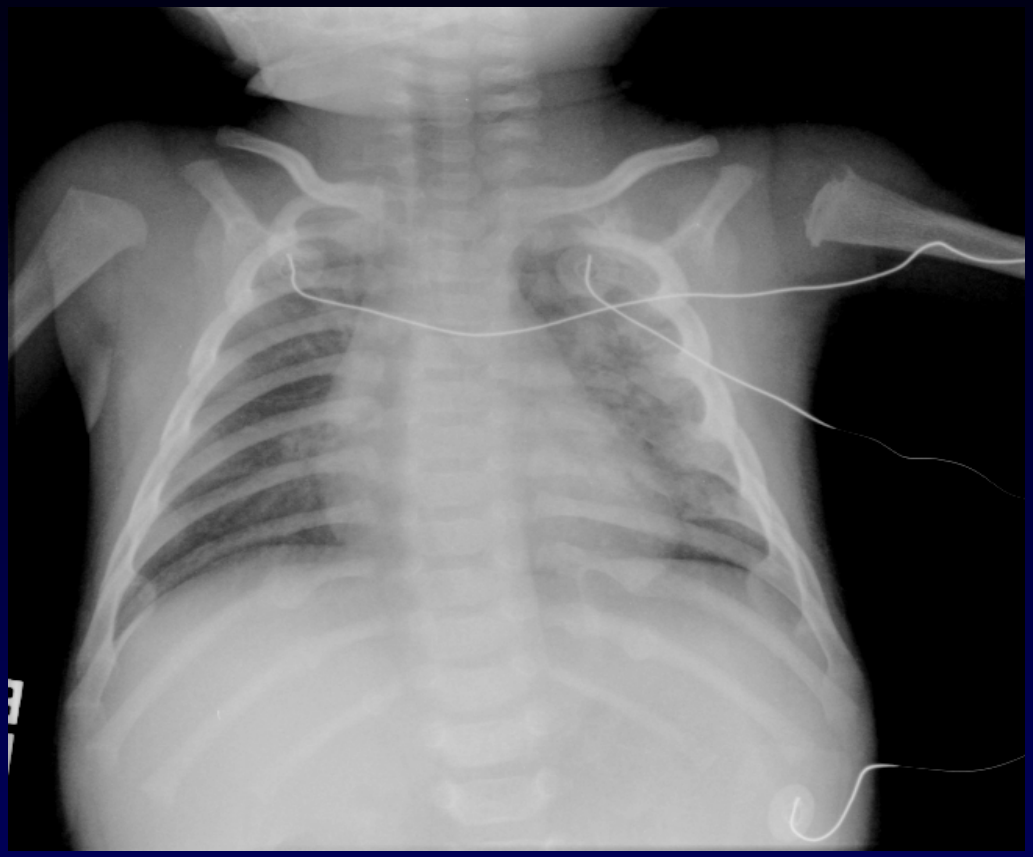

RSNA®
Radiological Society of North America
POLL INFORMATION SLIDE

Answer is E. **Multiple posterior and lateral rib fractures in different stages of healing and a metaphyseal corner fracture of the left proximal humerus**

The x-ray demonstrates normal bone mineralization with acute fractures of the posterior left 3rd-7th ribs, healing fractures of the posterior 9th-11th ribs, healing fractures of the right lateral 4-7th ribs and left 1st, 4-7, 9 and 10th ribs. There is also a metaphyseal corner fracture of the proximal left humerus.

Option A is not correct. The left upper lobe has acute posterior rib fractures, so what may appear to be consolidation may be a pulmonary contusion or hemorrhage.

Option B is not correct. The bone mineralization is radiographically normal, and the metaphyses are not cupped or frayed. There is a classic metaphyseal lesion (corner fracture) of the left proximal humerus, but the right proximal humerus is normal. The appearance of metaphyseal cupping or fraying associated with rickets is distinctly different from the classic metaphyseal lesion.

Option C should be included, but noting that injuries are in different stages of healing provides important information regarding the chronicity and repetitive nature of the trauma. Option C does not include the metaphyseal fracture of the proximal left humerus, which should also be included in the report.

Option D should be included, but there are additional observations to include.

Option E is correct. **Multiple rib fractures in different stages of healing and a metaphyseal fracture in a child with normal bone mineralization is highly specific for inflicted trauma.**

References:

1. Barsness, KA, Cha, ED, Bensard, DD, et al. The positive predictive value of rib fractures as an indicator of nonaccidental trauma in children. J Trauma. 2003; 54(6): 1107-1110.

2. Bulloch B, Schubert CJ, Brophy PD, et al. Cause and clinical characteristics of rib fractures in infants. Pediatrics 2000; 105(4): e48.

3. Pandya, NA, Baldwin, I., Kamath, AF, et al. Unexplained fractures: Child abuse or bone disease a systematic review. Clin Orthop Relat Res 2011; 469: 805-812.

4. Perez-Rossello, JM, Feldman, HA, Kleinman, PK, et al. Rachitic changes, demineralization and fracture risk in healthy infants and toddlers with vitamin d deficiency. Radiology 2012; 262(1): 234-241.

5. Sanchez, TR, Nguyen, H, Palacios, W, et al. Retrospective evaluation and dating of non-accidental rib fractures in infants. Clin Radiol. 2013; 68(8): e467-471.

Which of the following is true regarding the findings?

A. Classic metaphyseal lesion indicative of child abuse
B. Normal variant
C. Fracture seen in rickets
D. Osteomyelitis
E. Fracture not associated with child abuse

RSNA®
Radiological Society of North America
POLL INFORMATION SLIDE

Answer is A. **Classic metaphyseal lesion indicative of child abuse**

The radiograph depicts a **classic metaphyseal lesion which is characteristic of child abuse**. Abused infants commonly have metaphyseal injuries such as corner fractures due to the transmetaphyseal disruption of the trabeculae of the primary spongiosa.

Option A is correct. A localized bony fragment in the shape of a triangle is at the metaphyseal margin resulting from the planar injury at the metaphysis. This injury will appear as a bucket handle fracture in the orthogonal projection. These injuries are commonly found in abused infants.

Option B is <u>not</u> correct. The finding represents a classic metaphyseal lesion.

Option C is <u>not</u> correct. Classic metaphyseal lesions are not associated with rickets. In addition, there are no other radiologic findings to suggest rickets.

Option D is <u>not</u> correct. Osteomyelitis results in periosteal reaction and changes in the bony matrix.

Option E is <u>not</u> correct. Classic metaphyseal lesions represent fractures that are associated with child abuse.

References:

1. Kleinman Problems in the diagnosis of metaphyseal fractures Pediatr Radiol (2008) 38 (Suppl 3):S388–S394

2. Kleinman PK, Perez-Rosello JM, Newton AW, Feldman HA, Kleinman PL. Prevalence of the classic metaphyseal lesion in infants at low versus high risk for abuse. AJR 2011 October 197:1005-1008

3. Schilling S, Wood JN, Levine MA Langdon D, Christian CW Vitamin D status in abuse and nonabused children younger than 2 years old with fractures. Pediatrics 2011 127:835-841